

A CASE OF SWIMMING POOL GRANULOMA

S. Racheva, St. Pavlov, I. Krasnaliev*

Sector of Education and Science, and Clinic of Dermatology and Venerology

*Department of General and Clinical Pathology

University of Medicine - Varna,

RESUME:

The described case is of an infected patient with proven atypical mycobacterial infection and with developed granulomatous clinical picture, localized on the distal upper limb. The infection started several weeks after skin contact with aquarium water and a skin cut. Several nodular, purple reddish lesions developed, which spread and formed a compact mass of about 3 cm. Wrongly diagnosed, the patient was subjected to numerous unsuccessful treatments for six years.

The patient was diagnosed after a histological test.

The treatment started initially with Vibramycin, which was not effective enough. It continued with Claritromycin and after a 90-day therapy led to the complete disappearance of the nodular lesions on the skin.

Key Words: Swimming pool granuloma, *Mycobacterium marinum* - infection, Atypical mycobacterial skin infection, treatment

INTRODUCTION:

The Swimming pool granuloma is a chronic skin infection caused by *Mycobacterium marinum* (atypical mycobacteria). The bacteria are found in fresh, aquarium and sea waters and in some fish species. They cause an infection in fish and humans. It permeates broken skin, and 3 – 4 weeks after the injury the infection develops, usually on the injured spots /upper and lower limbs/. The changes are specific of the skin; there are two types of changes – single painless granulomas or a lymphangitic type of skin damage.

The disease is rare (12), mainly in people whose professions keep them in contact with water basins or fish or others who breed fish as a hobby. It evolves slowly and often remains undiagnosed for a long time (16). Another risky factor is the immune deficiency: HIV infection, leukemia, lymphoma, immunosuppressive therapy (10). The direct infection and its development are rare in Europe and North America (10), and some authors determine it as an epidemiologic disease (13). In the Bulgarian dermatologic literature only one case of the infection is described (1).

Case Description:

RTI, a 50-year-old person with a six-year-long disease. The disease appeared after a cut on a glass tank, in which

he bred decorative fish. Several weeks after the cut healed, around the cicatrix two-three painless, reddish, thick knots appeared that seemed to spread and grow. Some unsuccessful attempts at treatment were made, and various diagnoses were given.

Somatic Status: normal

Dermatologic Status: Dorsal changes on the skin are found at the base of the little finger on the right hand, between the fingers and on the back of the hand, as well as over the interphalangeal joint of the same finger. On erythema base are formed several overlapping, thick, bright red knots, indiscretely infiltrated.

The periphery of the formations is lividly brownish. There is no data of lymphangitis or enlarged lymph nodes. (Figure.1).

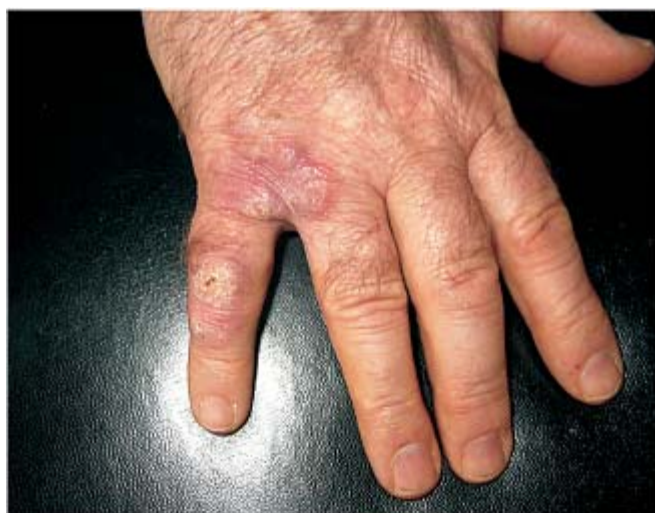

Figure 1.

Paraclinical data – within the norms.

Roentgenography of the bone structure of the infected finger – no data of osteomyelitic changes.

Mantoux reaction - negative.

Histological Test ¹ 1122 /2005: a strip of skin with hyperkeratosis, focal hypergranulosis and acantosis in the epidermis. In the dermis – moderately expressed exitosis, focal

ulceration, expressed mainly perivascularly, and periadnexal infection infiltrate of lymphocytes and leucocytes. Non-caseous epitheloid cellular granulomas with random gigantic cells of the Langerhans type. Some of the granulomas are with central abscess. No mycotic microorganisms were found upon coloring with PAS (Figure 2).

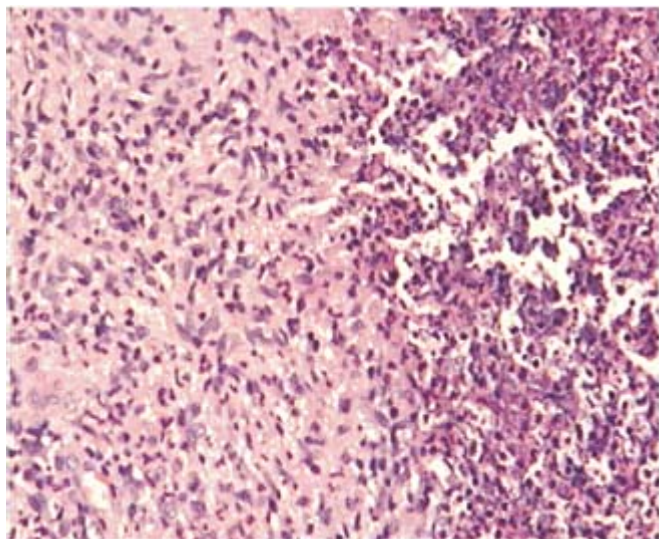


Figure 2. (x 100 HE)

On the grounds of the clinic picture, the initial contact with aquarium water of an open skin injury, and the histological founding, it was assumed that the case in question was of Swimming pool granuloma.

A long-term treatment was applied: after a 42-day therapy with Vibramycin (initially 200 mg daily, later – 100 mg daily) a considerable decrease of the infiltrate and the size of the knots was achieved (Figure 3.).

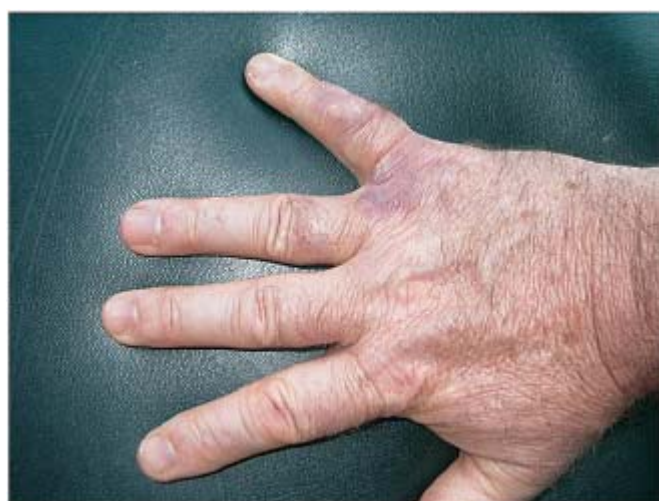

Figure 3.

After 45 more days of Claritromycin application (1 tabl 500 mg), the knot-like infiltrates were completely reduced.(Figure 4).

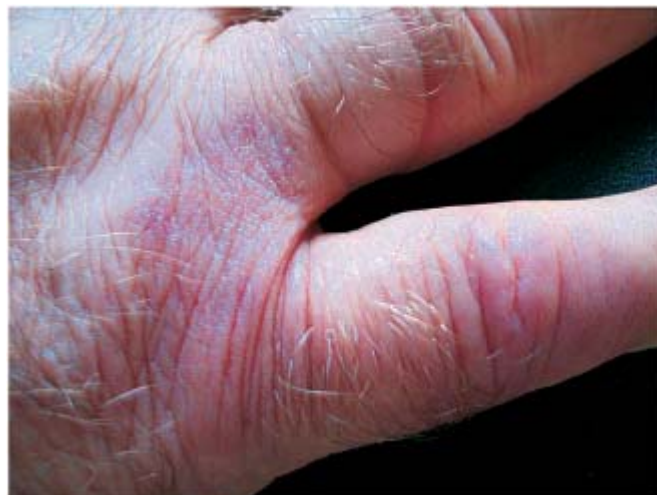

Figure 4.

DISCUSSION:

The described case follows the classic development of Swimming pool granuloma – breeding decorative fish, injury and tainting with aquarium water, slow and lengthy development of granuloma changes of the skin on the hand. Similar clinical pictures after a hobby activity are described in literature (15, 6, 3), but the direct infection happens more often under professional circumstances (7, 15).

The infection affects more often the upper limbs – up to 90% of the cases (5, 20), as is demonstrated in the described case, and less often – the lower limbs (17). The granuloma skin lesions, presented as purple red, nodular changes are observed in 63% of the infected with Swimming pool granuloma (5); very rarely are observed cases of lymphangitis only, or in combination with granulomas (5, 11) or joint damage with the respective symptoms, as well as disseminated cases (14). In some cases the granuloma knots are inclined to ulcerate, especially in a lengthy process (3, 18). Cases of associating and mistaking the Swimming pool granuloma with Erythema nodosum are described (9). In our case, the compact nodular change is with comparatively small dimensions, without ulceration and damage of the joint or the bone structure.

Out of the various diagnostic methods – culture test, fast molecular method, Polymerase chain reaction (19), of most importance is the histological test of the nodular skin lesion (16). Doubtlessly, the histological picture reveals considerable differences of the clinically formed granuloma depending on its shorter or longer existence. With the described case, which has a six-year-old history, the

histological result is typical and unquestionable to diagnose.

The means and methods of treatment of the mycobacterial infection are various. Predominant is the opinion of the very good efficiency of Rifampin or a combination of Rifampin with Etambutol (4). Edelstein H. (1994) recommends this combination as the best, effective in 71% of the treated. Good results have been achieved with Minocin (20, 5), which is supported also by in vivo tests of the susceptibility of *Mycobacterium marinum* to various antibiotics (2). The quinolones can be used as a means of choosing (8) a treatment of Swimming pool granuloma.

There are authors who support the surgical intervention (17), when it is necessary.

It should not be ignored that sometimes the good combination of Rifampin+Etambutol fails (17).

This makes necessary the individual approach to the choice of an antibiotic. Besides, it should be taken into account that the nodular changes on the hands in cases of

Swimming pool granuloma are more resistant and less susceptible to treatment (20).

During the treatment of the observed case, the 42-day therapy with Vibramycin showed slow improvement of the clinical data, whereas the subsequent therapy with Claritromycin had a considerably better effect on the nodular lesions until their complete reverse development. The lengthy existence of the infection made necessary a longer 90-day treatment, which was successful.

CONCLUSIONS:

With Swimming pool granuloma the length of the infection, the frequent visits to physicians, and the many - and multifarious - medicaments, have to be the starting points for a search for a *Mycobacterium marinum* infection.

For the treatment of Swimming pool granuloma the most effective medicaments as well as the length of the disease and the individual reaction to a specific antibiotic have to be taken into account.

BIBLIOGRAPHY:

1. Tomov Sh, Karayashv G, Tomov G, Swimming pool granuloma, *Dermatol and Venerol*, 2001, 1, 23-25.
2. Arai H, Nakajima H, Kaminaga Y, In vitro susceptibility of *Mycobacterium marinum* to dihydromycoplanecin A and ten other antimicrobial agents, *J Dermatol*, 1990, 17, 6, 370-4.
3. Boisten P, Brinkmann W, Swimming pool granuloma – a mycobacteriosis, *Z Hautkr*, 1985, 60 (1-2), 105-8.
4. Donta ST, Smith PW, Levitz RE, Quintiliani R, Therapy of *Mycobacterium marinum* infections. Use of tetracyclines us rifampin, *Arch Intern Med*, 1986, 146 (5), 902-4.
5. Edelstein H, *Mycobacterium marinum* skin infections. Report of 31 cases and review of the literature, *Arch Intern Med*, 1994, 27, 154 (12), 1359-64.
6. Esmann J, Christiansen JV, Skin infection with atypical *Mycobacteria*. Swimming pool/aquarium granuloma, *Ugeskr Laeger*, 1988, 29, 150 (9), 551-9.
7. Fischer AA, Swimming pool granulomas due to *Mycobacterium marinum* & an occupational hazard of lifeguards, *Cutis*, 1988, 41 (6), 397-8.
8. Garcia- Rodriguez JA, Gomez Garcia AC, In vitro activities of quinolones against mycobacteria, *J Antimicrob Chemother*, 1993, 32 (6), 797-808.
9. Garty B, Swimming pool granuloma associated with erythema nodosum, *Cutis*, 1991, 47 (5), 314- 6.
10. Gbery IP, Djeha D, Yobouet P, Aka B, Kanga JM, Atypical mycobacterial skin infections, *Sante*, 1996, 6 (5), 317 -22.
11. Gray SF, Smith RS, Reynolds NJ, Fish tank granuloma, *Br Med J*, 1990, 300, 1069 – 1070.
12. Hausser M, Ippen A, Swimming pool granuloma, *Hautarzt*, 1985, 36 (8), 436-40.
13. Kern W, Vanek E, Jungbluth H, Fish breeder granuloma: infection caused by *Mycobacterium marinum* and other atypical mycobacteria in the human, *Med Klin (Munich)*, 1989, 15,84 (12), 578-83.
14. King AJ, Fairley JA, Rasmussen JE, Disseminated cutaneous *M. marinum* infection, *Arch Dermatol*, 1983, 119, 263-270.
15. Kullavanijaya P, Sirimachan S, Bhuddhavudihikrai P, *Mycobacterium marinum* cutaneous infections aquired from occupations and hobbies, *Int J Dermatol*, 1993, 32 (7), 504-7.
16. Leuenberger R, Bodmer T, Clinical presentation and therapy of *Mycobacterium marinum* infection as seen in 12 cases, *Dtsch Med Wochenschr*, 2000, 7, 125 (1-2), 7—10.
17. Ljungberg B, Christensson B, Grubb R, Failure of doxycycline treatment in aquarium- associated *Mycobacterium marinum* infections, *Scand J Infect Dis*, 1987, 19 (5), 539 – 43.
18. Loria PR, Minocyclin hydrochlorid treatment for atypical acid-fast infection, *Arch Dermatol*, 1976, 112, 517 – 519.
19. Posteraro B, Sanguinetti M, Garcovich A, Ardito F, Zampetti A, Masucci L, Sbordoni G, Cerimele D, Fadda G, Polymerase chain reaction – reverse cross hybridization assay in the diagnosis of sporotrichoid *Mycobacterium marinum* infection, *Br J Dermatol*, 1998, 139 (5), 872 – 6.
20. Ryan JM, Briant GD, Fish tank Granuloma – a frequently misdiagnosed infection of the upper limb, *J Accid Emerg Med*, 1997, 14 (6), 398 – 400.